Hybrid spinoffs in Pacing and Lead extraction

Muneretto Claudio - Bontempi Luca , MD

Division and Chair of Cardiosurgery and Cardiology

Electrostimulation and Electrophysiology Laboratory

Brescia – Italy

MAM 2017 – The Epicardial Chapter
MULTIDISCIPLINARY ARRHYTHMIA MEETING
NOVEMBER 2 – 3, 2017
ZURICH, SWITZERLAND
2017

The rate of implant

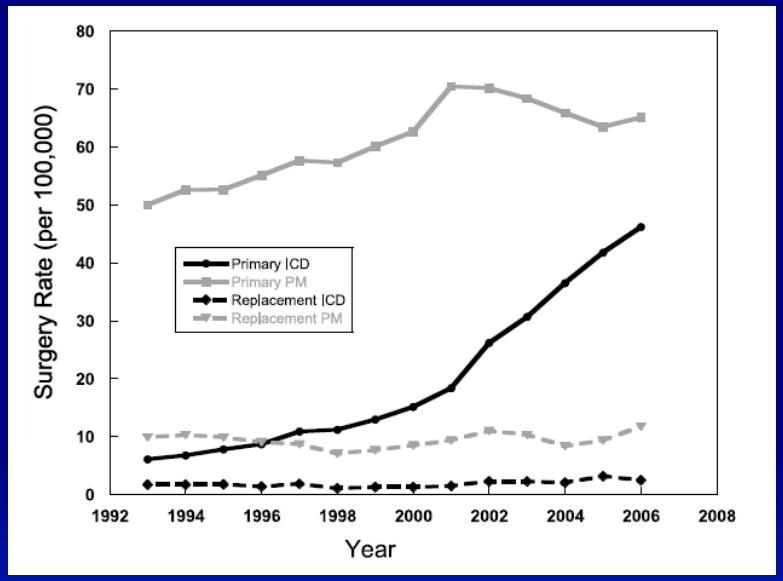

S. Kurtz et Al, Vol. 33 PACE 2010

Pts health profile

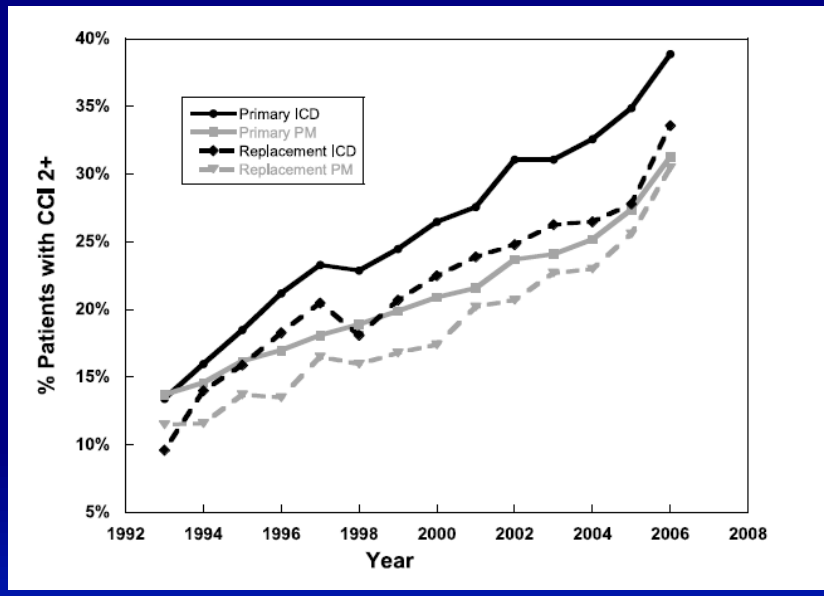

J Am Coll Cardiol 2012;60:1540–5)

Procedere	Mean age
Primary PM	75 ± 12.1
Replacent PM	73 ± 16.0
Primary ICD	66.2 ±12.8
Replacent ICD	67.9 ± 13.2

Age of PM Pts at Time of Implantation

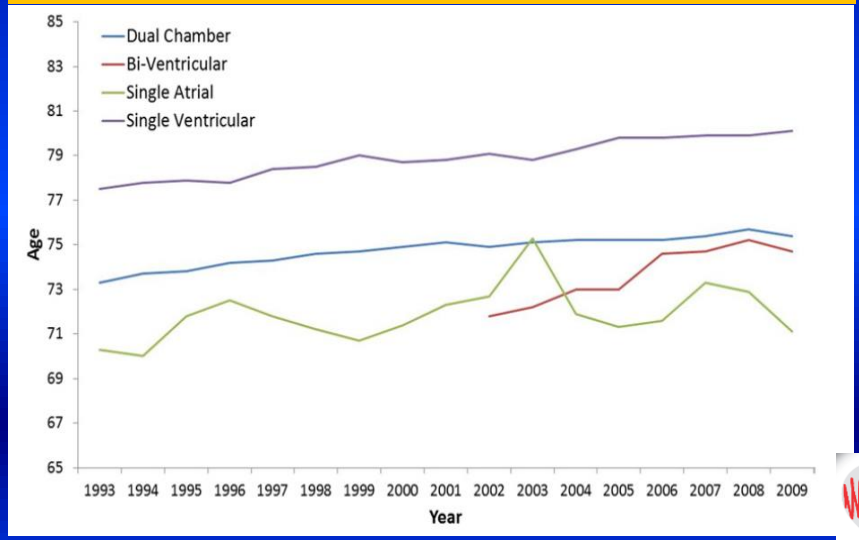

Today:

- 3.25 mln PM
- 180.000 ICD
- 400.000 - 500.000 new implants / year

Implant's complications

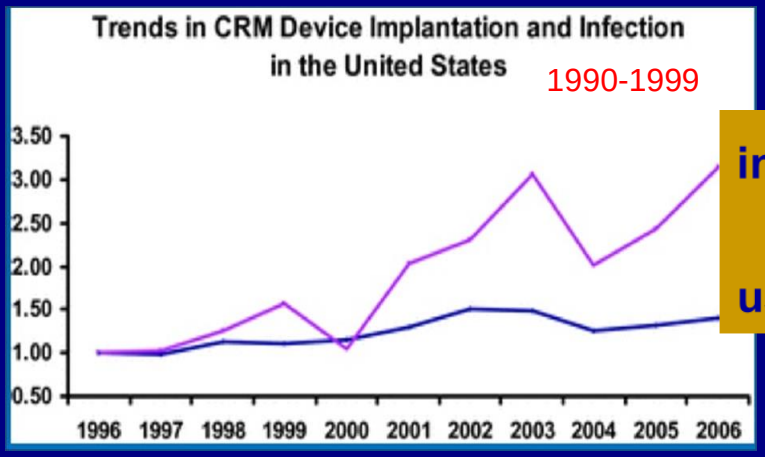

infections : + 124% (P<0.001 for trend)

use : + 42% (P< 0.001 for trend)

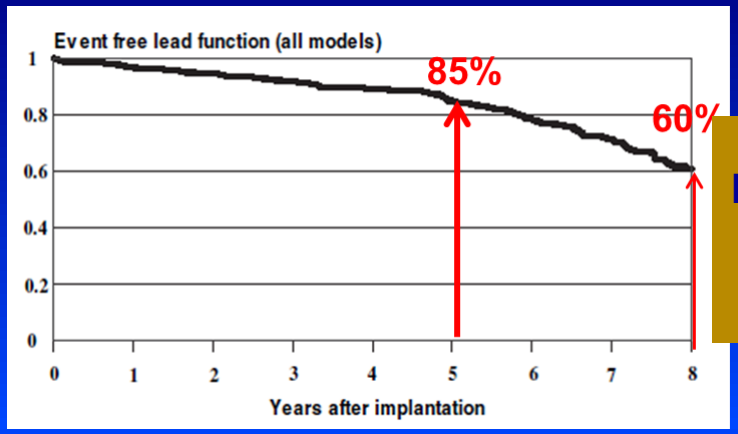

PM 28% at 10 years

ICD 40% at 8 years

Venous trombosis	15 - 40%

Accufix

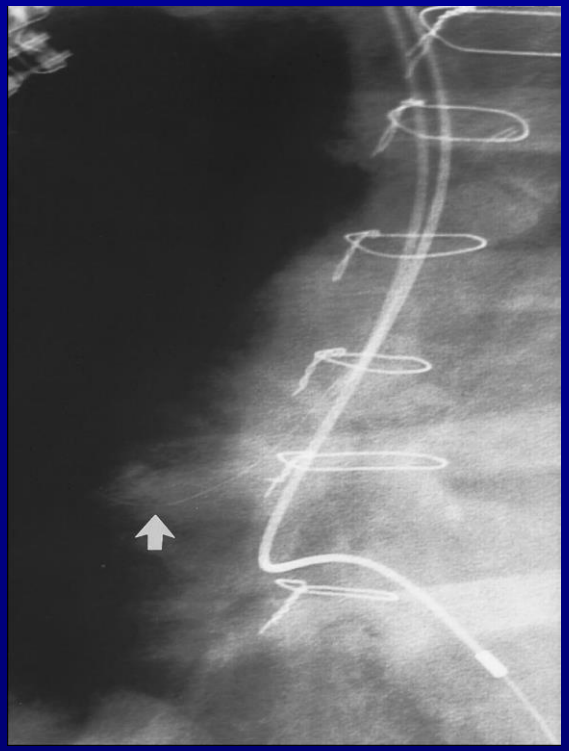

Riata St Jude Medical

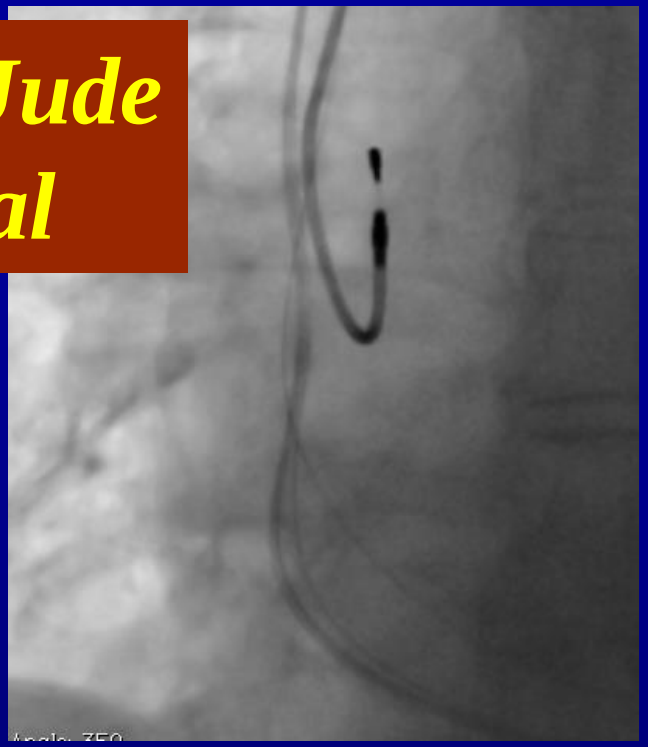

Sprintfidelis Medtronic ICD lead

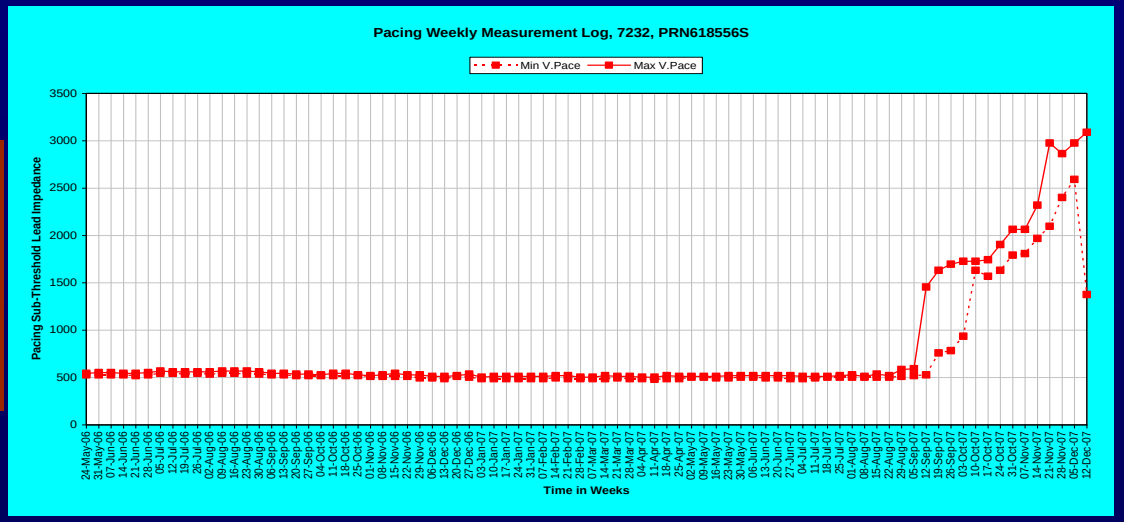

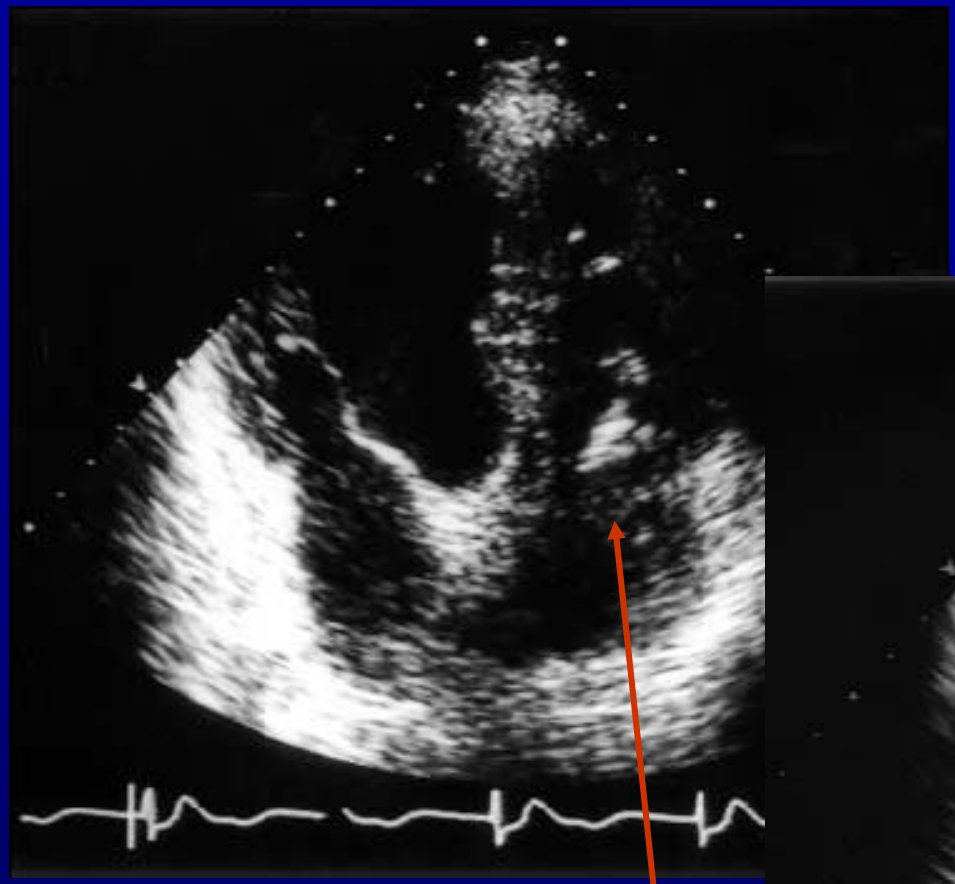

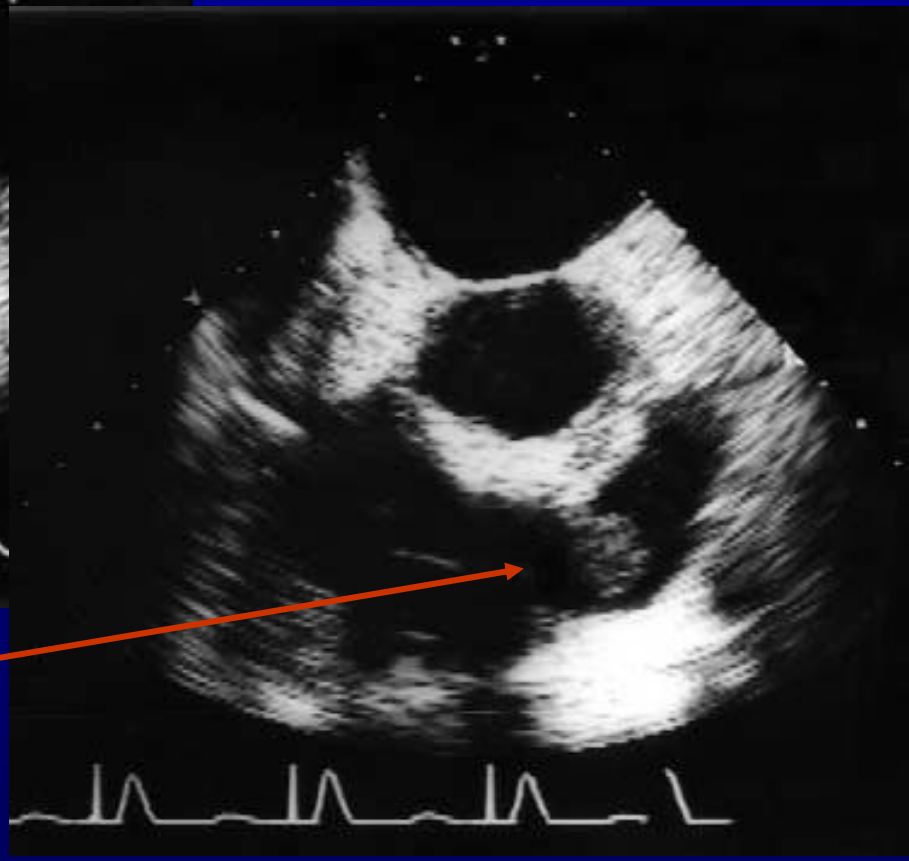

Lead's Endocarditis

Leads extraction : efficacy and safety

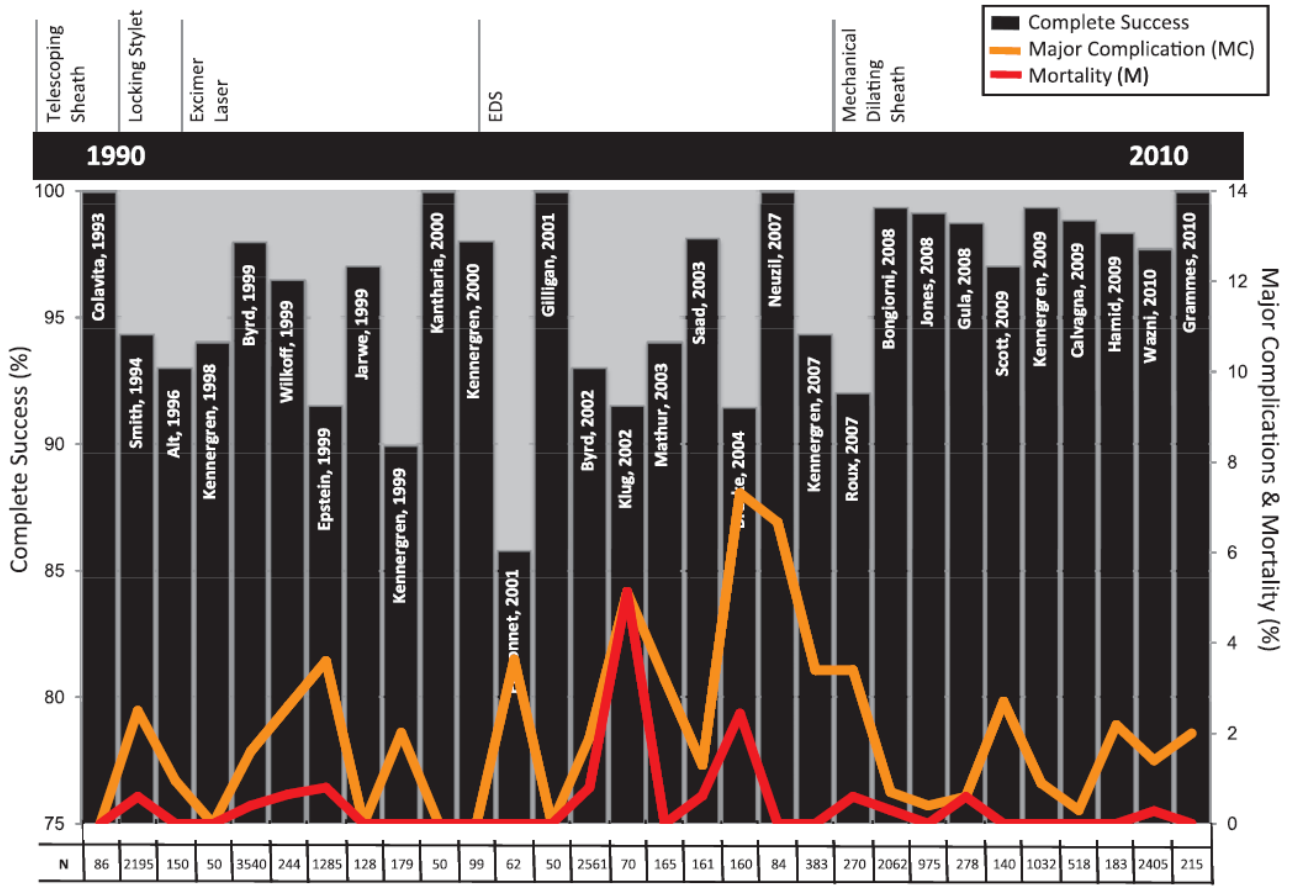

Figure 1 Success, morbidity and mortality in large series. Graphic representation of complete success as a function of time, represented by black columns. Secondary y axis represents percentage morbidity (orange) and mortality (red). Timeline of extraction techniques and tools commensurate with reported trials is at the top of the figure. Values below the graph represent the number of leads (N) extracted in each study. Composite major complication (MC) and mortality (M) rate was calculated. Only studies with ≥50 leads extracted *and* data regarding mortality and major complications were included.

Lead Extraction is preferred for Lead revisions and System Upgrades – When Less is More
Maytin M et al, Circ Arrhythm Electrophysiol. 2010; 3:413-424

LEADS EXTRACTION

- ***Risk of interference***
- ***Risk of shunt of delivered energy***
- ***Risk of venous trombosis***
- ***Difficult future access to the great veins***

Risks and benefits of extraction need to be well weighed against the risk of a retaining in situ

- ***High Risk Patients***
- ***Encasement of proximal coil at VCS level***
- ***Adherences:***
  - ***Distal coil***
  - ***Tip***

Extraction Tecniques

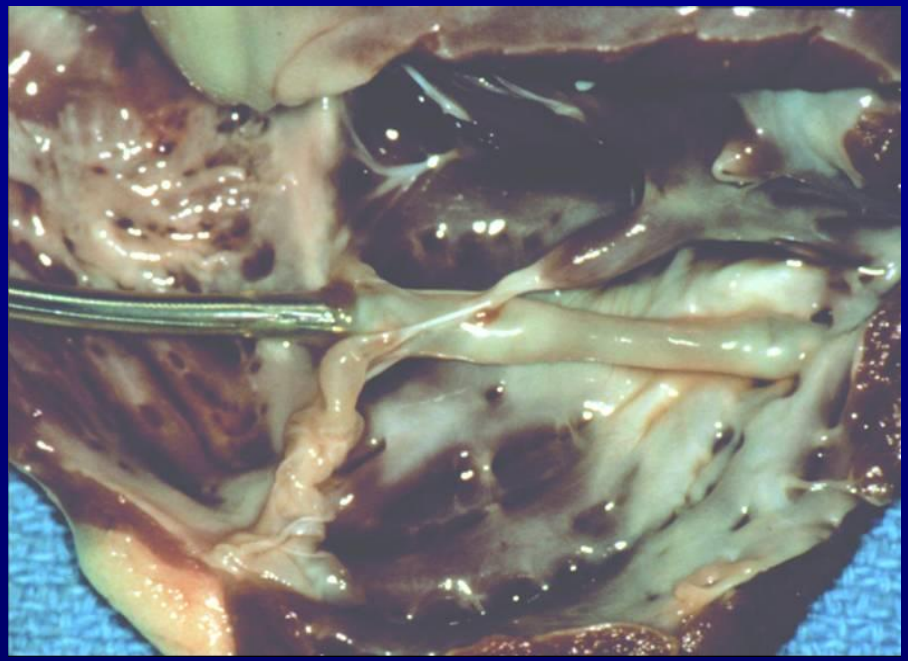

Intraventricular fibrosis

Traction

Countertraction

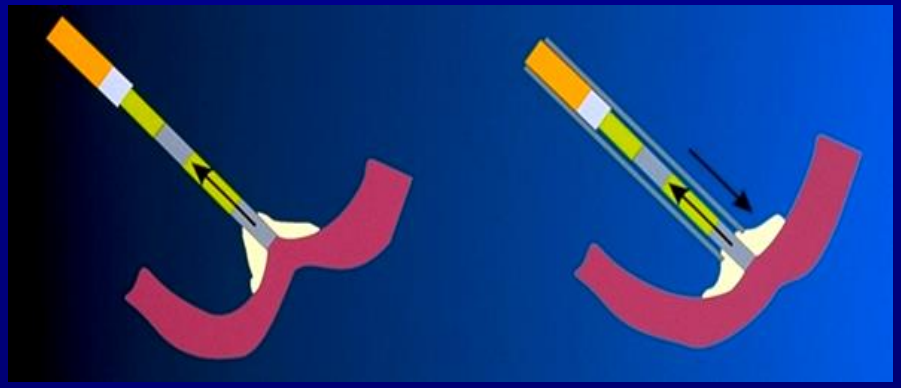

Pulling on the lead may invert the Heart or tear myocardium

Pull the lead, push the outer sheath; localizes shearing force on scar

Mechanical Sheaths :

metal /teflon/ polyproylene: require manual advancement

over the lead and rely on the mechanical properties of the

sheat to disrupt fibrotic attachments



Powered Sheath

- Rotating Threaded Tip Sheat : rotationally powered mechanism on the tip

- Electrosurgical dissection sheath (EDS): radiofrequency energy emitted between two electrodes at the sheat tip to disrupt the fibrotic attachments

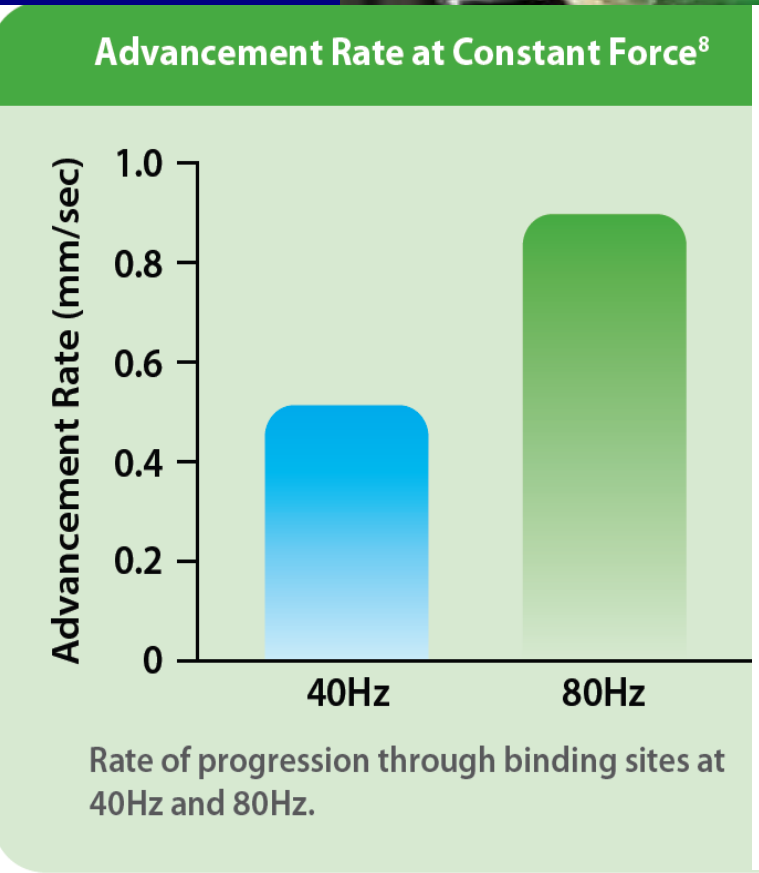

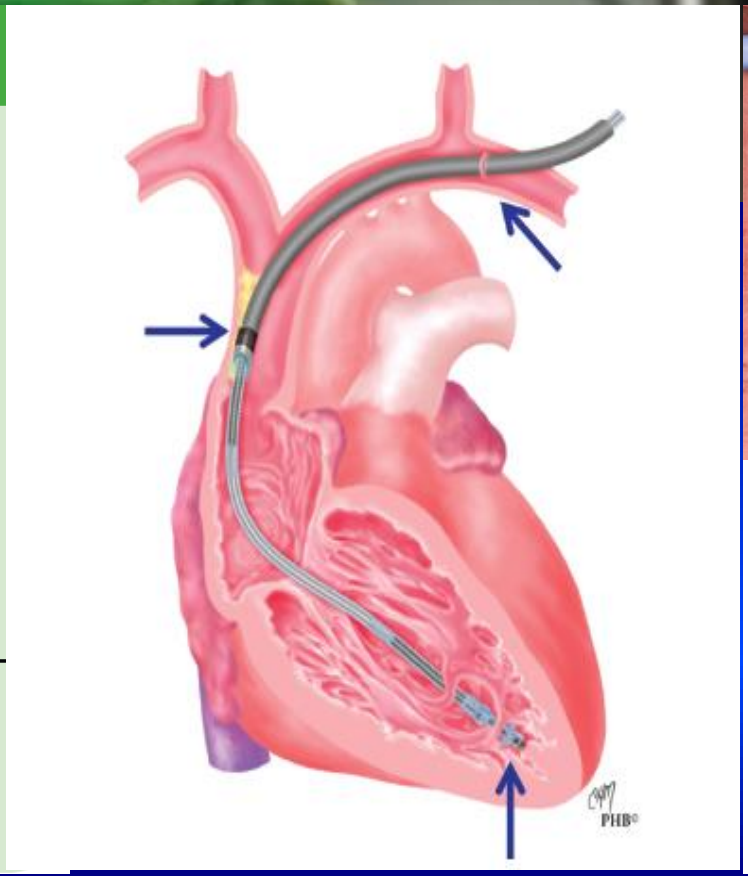

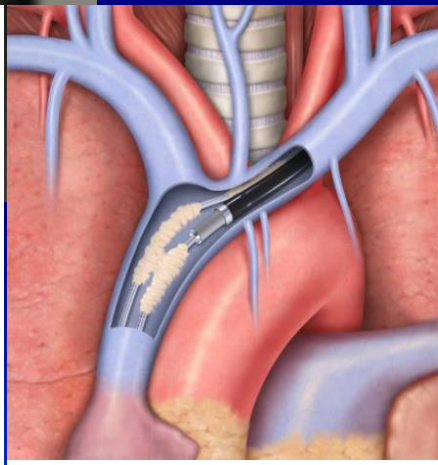

- employ fiberoptics to transmit laser lite
- to disrupt the fibrotic attachments

Lead Extraction Approach

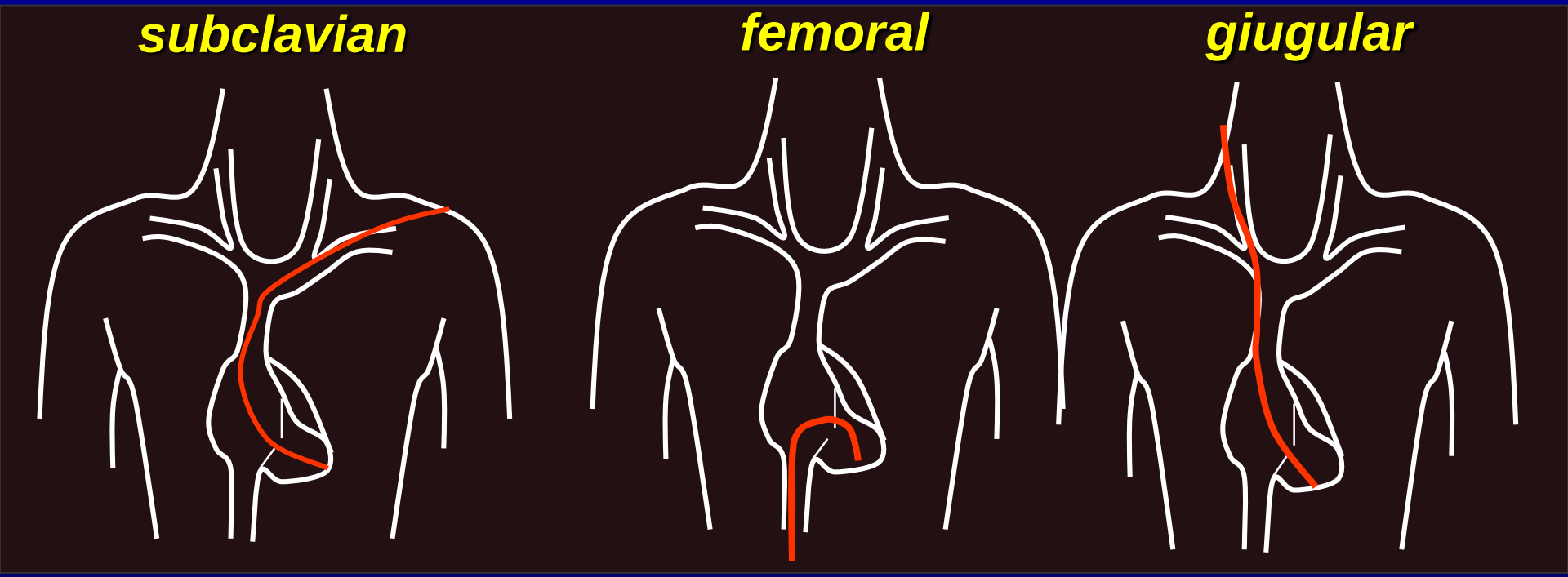

cortesy of M.G Bongiorni- Pisa -Italy

COMMON LOCATION OF COMPLICATION

•Subclavian vein tear /AV fistula

•Innominate tear /perforation

•High SVC tear /perforation

• SVC tear /perforation

•SVC/RA junction tear /perforation

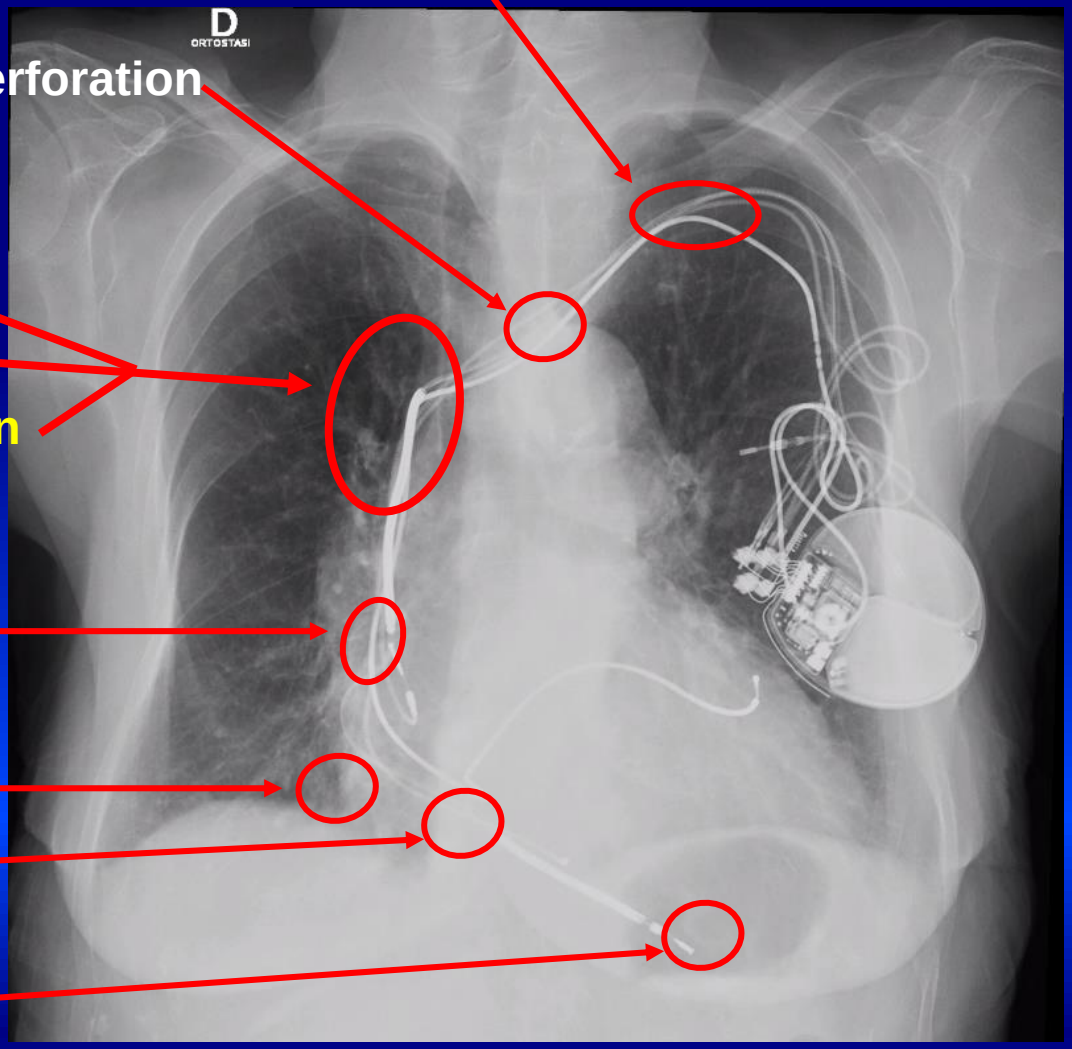

•Atrial wall perforation

•Inferior vena Cava

•Valvular damnage

•Ventricular wall perforation

Fibrosis

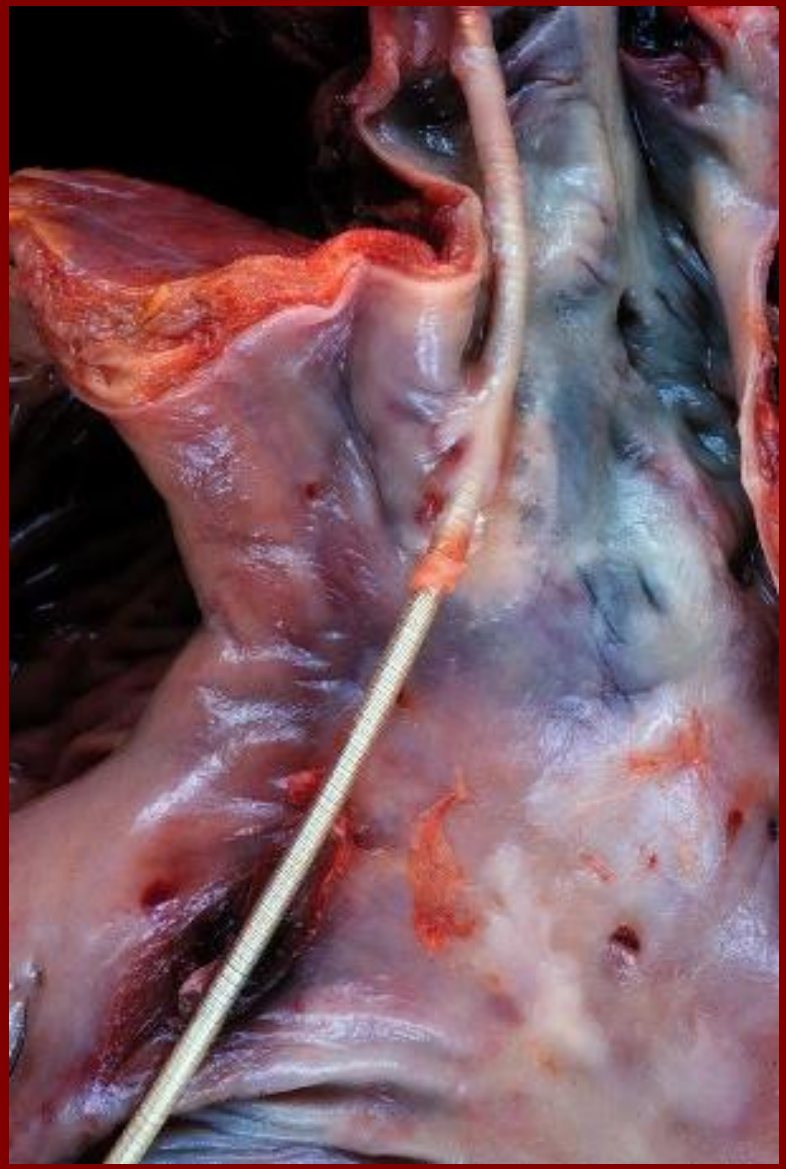

Calcifications

Lead through SVC and tricuspid valve encased in fibrous sheat

Hybrid approach in hybrid room

- **ENDOVASCULAR**

+

- **SURGICAL :**

- Minithoracotomy
- Thoracoscopy
- General anesthesia

Hybrid Minimally Invasive Approach for Transvenous Lead Extraction: A Feasible Technique in High-Risk Patients

LUCA BONTEMPI, M.D.,* FRANCESCA VASSANELLI, M.D.,* MANUEL CERINI, M.D.,* GIANLUIGI BISLERI, M.D.,† ALBERTO REPOSSINI, M.D.,† LAURA GIROLETTI, M.D.,† LORENZA INAMA, M.D.,* FRANCESCA SALGHETTI, M.D.,* DARIA LIBERTO, M.D.,‡ DANIELE GIACOPELLI, M.Sc.,§ ABDALLAH RAWEH, M.D.,¶ CLAUDIO MUNERETTO, M.D.,† and ANTONIO CURNIS, M.D.*

12 Pts of planned hybrid lead extraction;

- **minithoracotomy on 10 (83%)**
- **Thoracoscopy on 2 (17%)**
- **A total of 25 leads out of 27 (median lead age 19 years) were successfully extracted with laser, mechanical or combined transvenous sheath.**

J Cardiovasc Electrophysiol, Vol. 28, pp. 466-473, April 2017

Hybrid approach

- **HIGTH RISK PATIENT**
  - Age pts
  - Comorbidity
  - Vein occlusion
  - LED SCORE > 10

- AGE OF LEAD > 15 AA
- No previos heart surgery
- Failure of previous extraction ……

HYBRID CLINICAL CASE

- 1991 : IMPLANT PM DDD FROM RIGHT SIDE
- 2008 : ATRIAL ACTIVE FIXATION
- 4 POKET REVISION FOR DECUBITUS IN 7 LAST MOUNTHS

HYBRID CLINICAL CASE

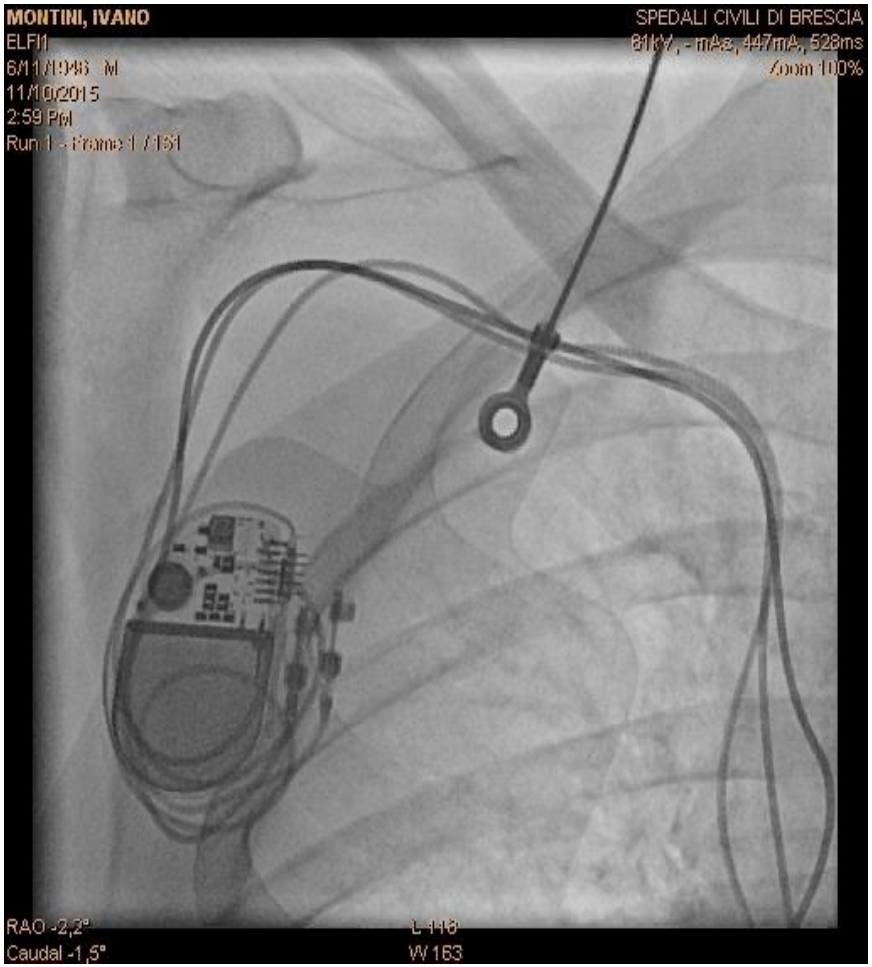

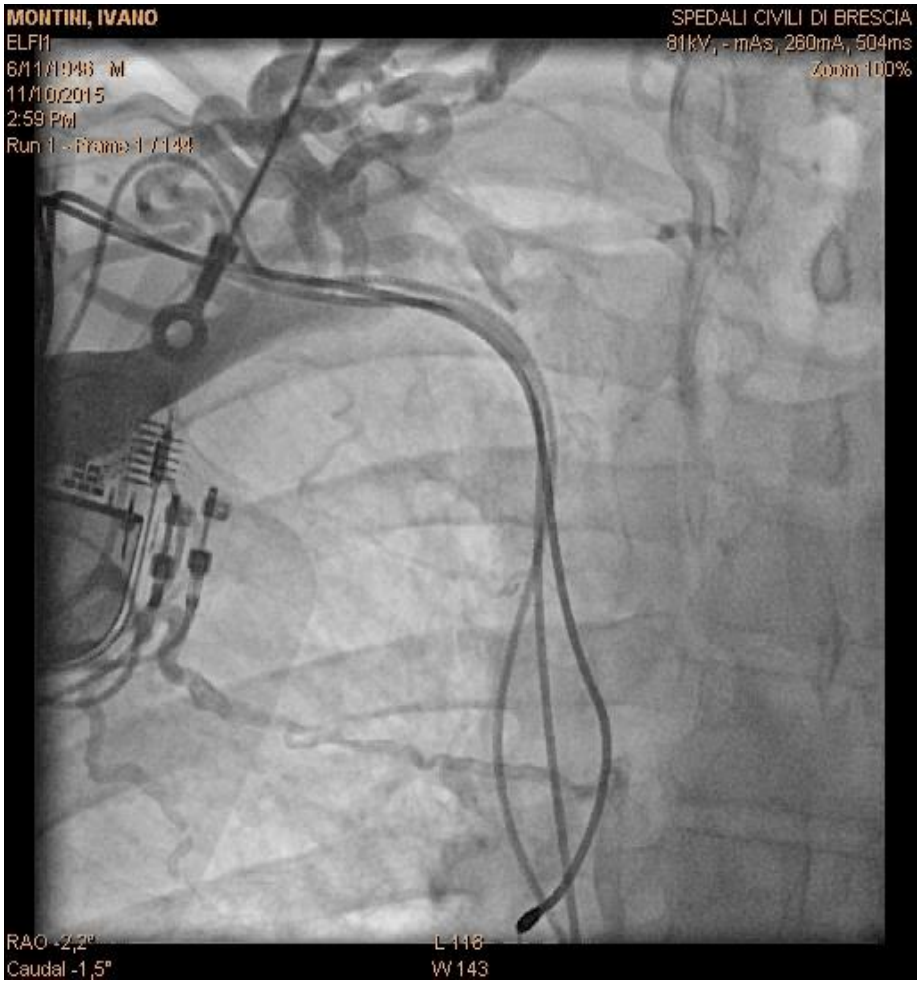

Positioning of LLD

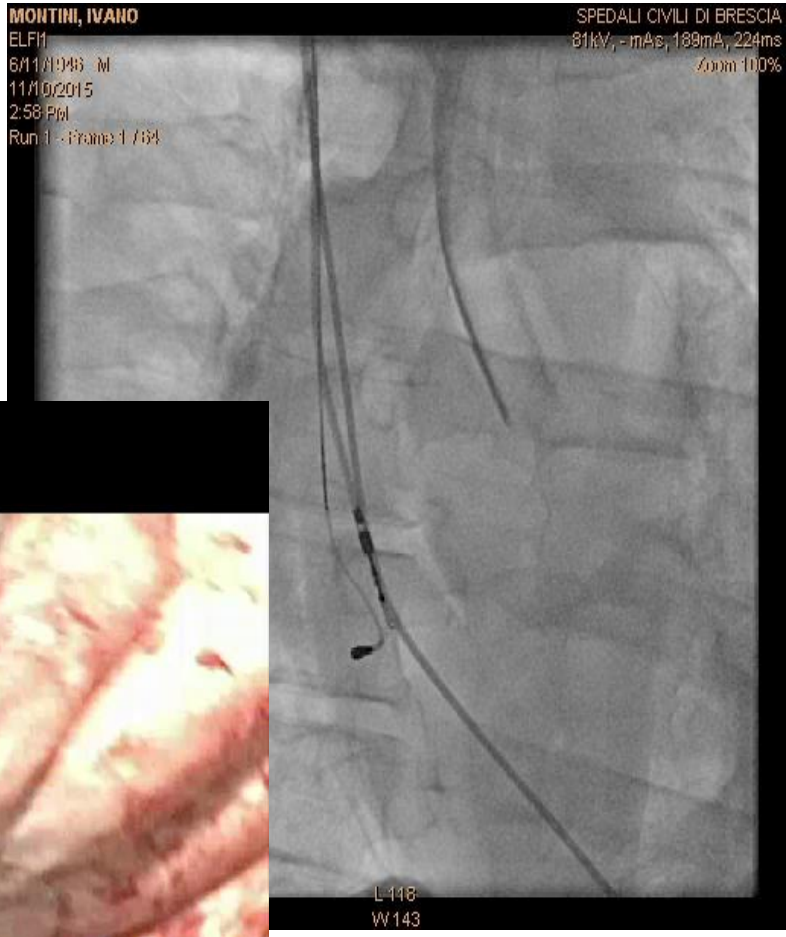

Atrial (2008) lead extraction

(Laser Sheat 12 F)

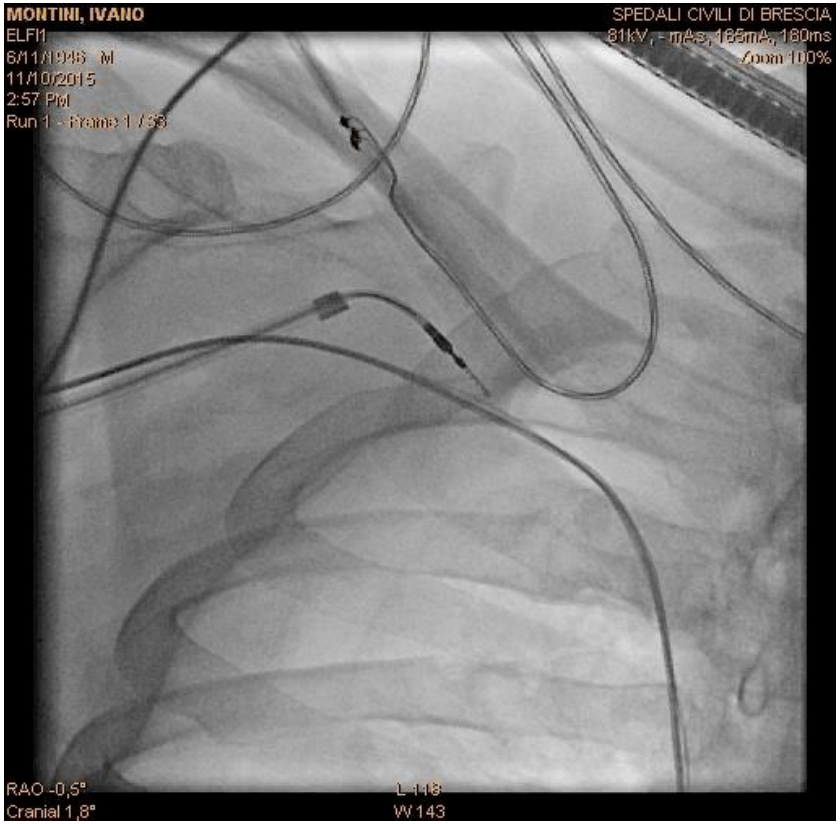

HYBRID CLINICAL CASE



RIGHT ATRIAL (1998)LEAD EXTRACTION : TRACTION

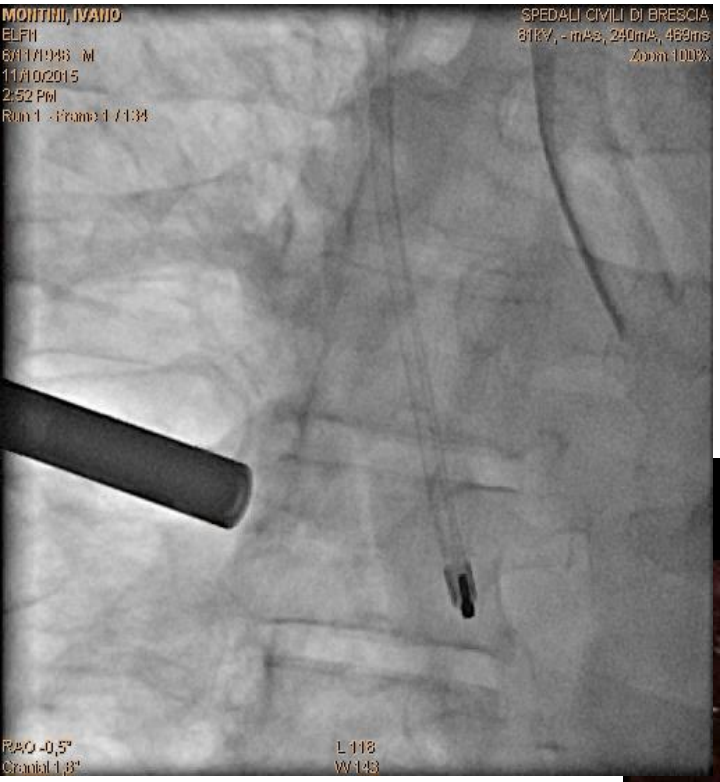

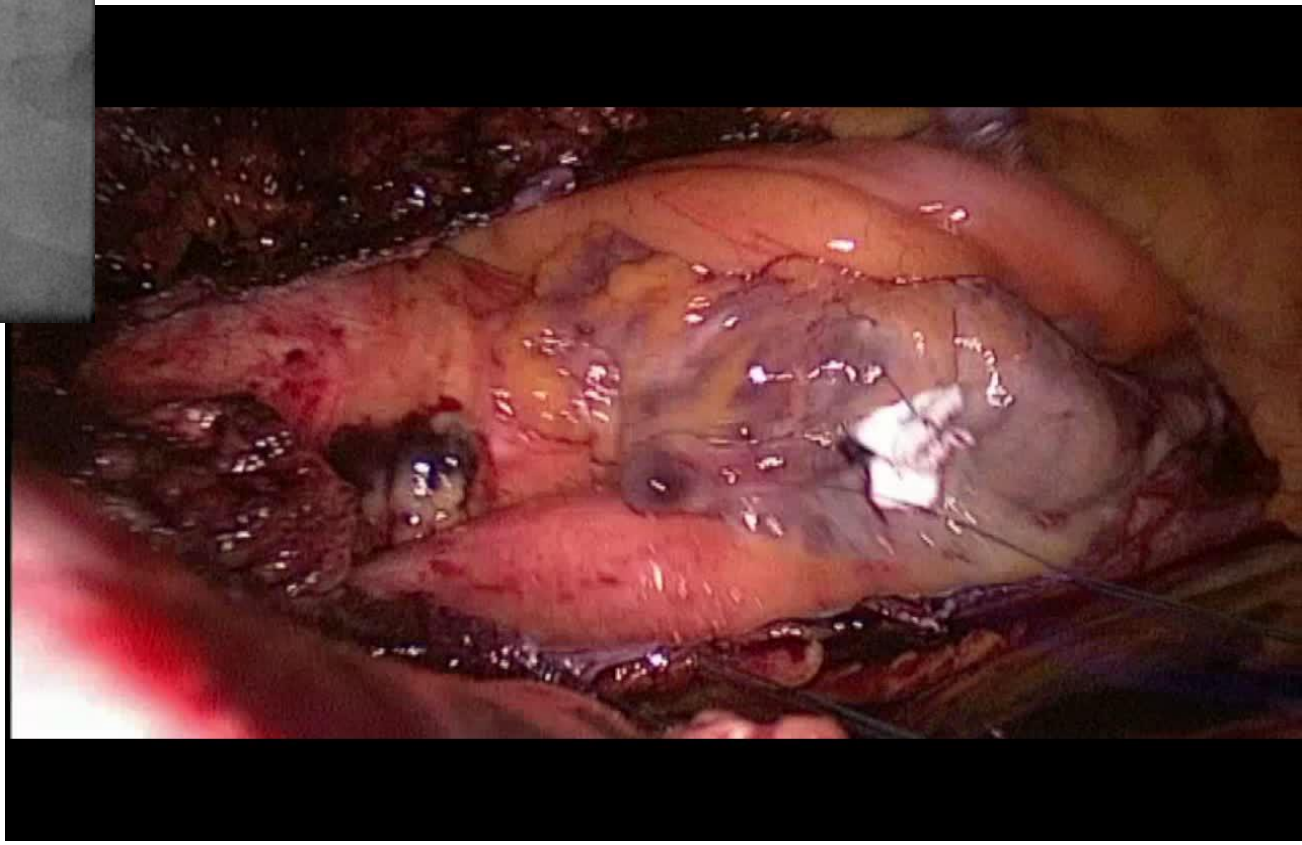

Conclusions

- The complete removal of the system is the more effective therapy for the eradication of complications divice-related (infections, malfunctioning).
- Different extraction tecniques were at the same level of efficacy and safety in the right hands.

Conclusions

Different endovascular and surgical approches are available for leads extraction, and the possibility of combinated use makes the therapy more effective and more safe.